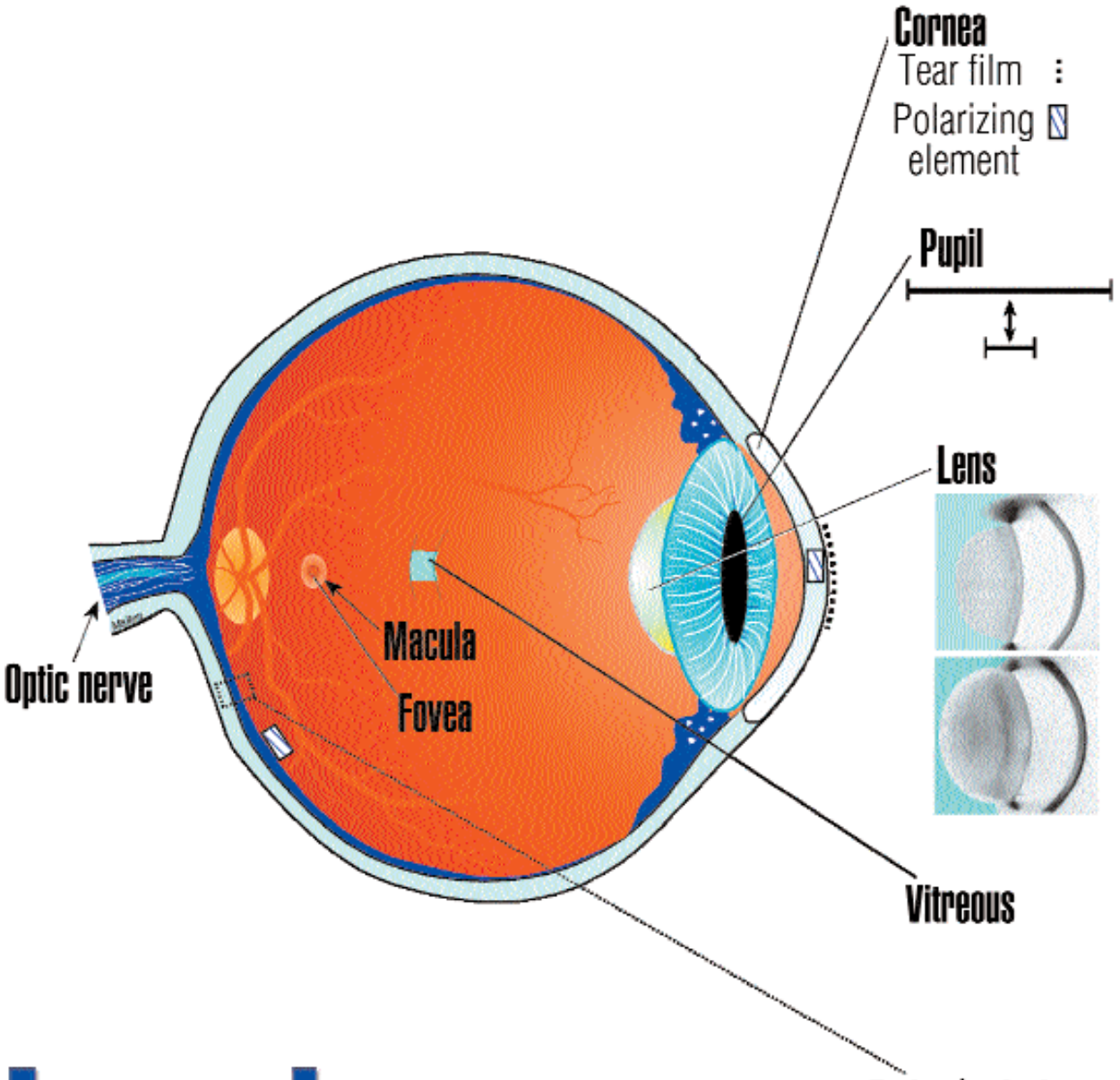

Imaging in the Aging Eye

By Ann E. Elsner, Andreas Remky, Joseph P. Walker, Glenn L. Wing, Paul A. Raskauskas, Donald C. Fletcher, Linda M. Kelley and Cheryl Kiesel

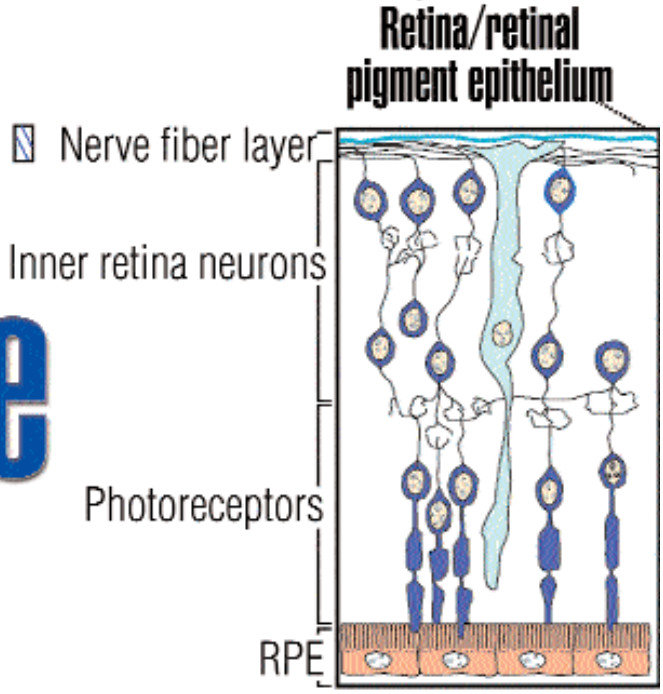

1047-6938/00/07/0020/06-$0015.00

Retinal imaging may seem a simple endeavor, given that the eye is far more transparent and accessible than internal organs such as the heart. Optical imaging techniques allow high resolution, with measurements of living tissues reported in microns, in comparison to magnetic resonance imaging. Most retinal imaging techniques are less invasive than endoscopy. There is a long-standing acceptance of retinal imaging as an important set of techniques in research and medicine.

Although the advantages listed above are indeed significant, the tissues in the living eye are exquisitely sensitive to light, and some of the tissues of interest are transparent. What's more, since the eye is the main organ for sensing light, its design is such that it is optimal for capturing light—not for reflecting it. Thus, even before the aging processes begin to destroy the eye's transparency, the chief problem is enhancing the contrast of the relatively transparent tissues in the retina, without damaging them with excessive radiation.

There is a long-standing acceptance of retinal imaging as an important set of techniques in research and medicine.

Retinal imaging encompasses a number of techniques, all with differing goals. The main applications include characterizing the basic anatomy and physiology of the retina, understanding vision changes caused by aging or disease, discovering disease mechanisms, and providing improved care for patients with sight-threatening disease. Since the eye offers the clearest view of living human neural tissue and blood circulation, emerging techniques use the eye as a window to the health of an individual. In recent years, modern photonics have led to advances in each of these areas, although no single technique is optimal for all applications.

Matching the techniques to the problems

As the population of the United States ages, medical diagnosis is becoming the primary application of retinal imaging. Age-related changes to the structures of the eye put constraints on retinal imaging. These changes go beyond tissue disruption caused by disease processes. Figure 1 (opposite) illustrates the path of light through the eye, as well as some of the well-known changes that characterize the aging eye.

The healthy human retina is a mostly transparent structure with many layers of densely packed and well-

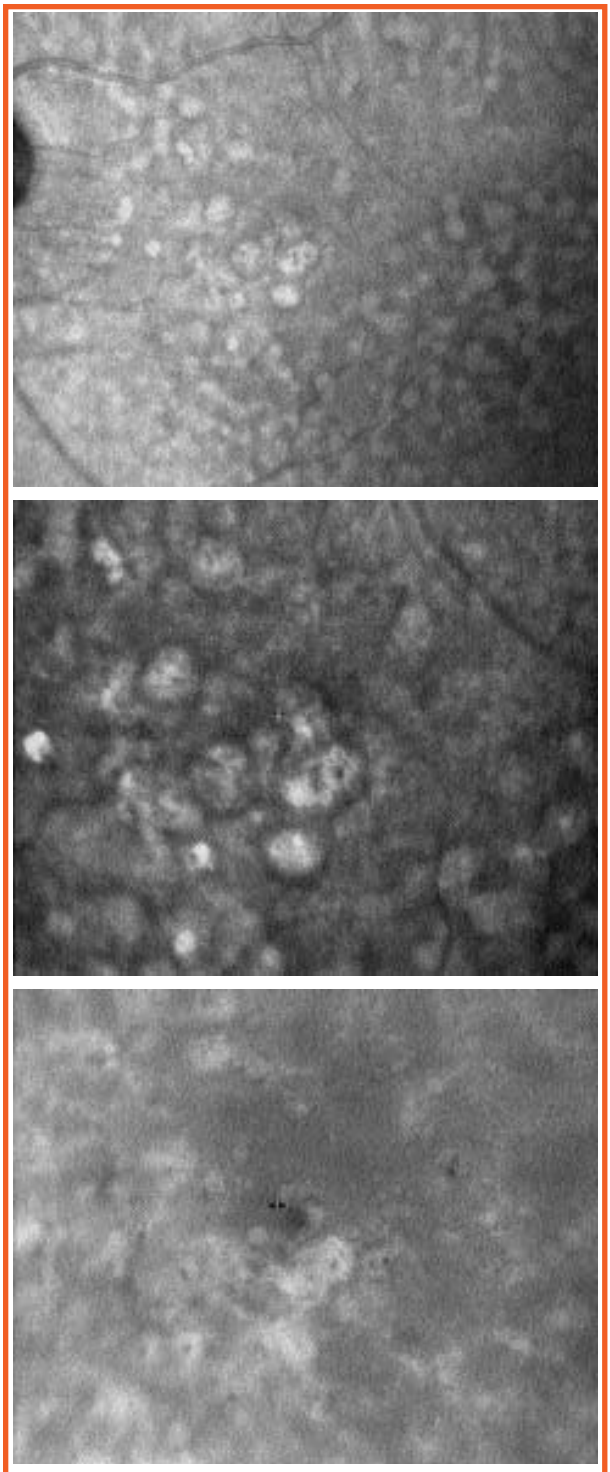

Figure 2. Imaging of the retina of a patient with age-related macular degeneration, with a five-year longitudinal study made possible by using a technique that has minimal artifacts due to developing cataracts. The top panel shows a 790 nm image that covers about 40 degrees visual angle of retina. The large whitish spots are deposits beneath the retina, the clinical hallmark of this disease. The middle panel shows a more magnified view, 20 degrees. The bottom panel shows another 20 degree view, but this time with the retina illuminated with a 633 nm HeNe and only the multiply scattered light captured. The details of the superficial retina, such as most of the retinal blood vessels, are no longer visible, but certain types of pathological structures become more visible.

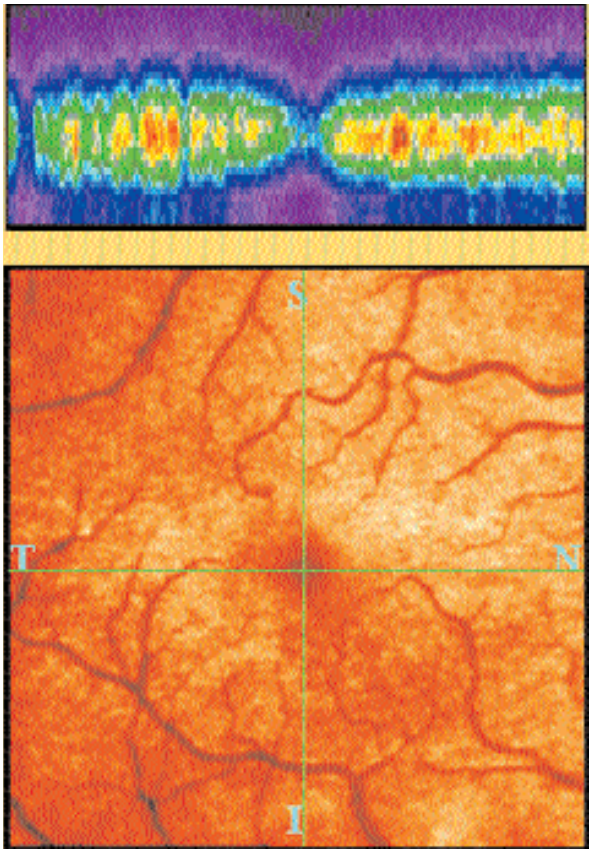

Figure 3. Confocal imaging of the retina of a normal subject, using an 850 nm VCSEL as the illumination. The image of the retina is the summary image for 32 images, collected as a series, with the focus varying in the axial dimension. A cross-sectional map of the intensity of each image is shown above in pseudo-color. The cross-hair on the retinal image indicates the location, horizontally through the foveal pit. Even with the longer wavelength, there is far less penetration into the deeper layers of the sample because of the relatively higher light return of the more anterior layers.

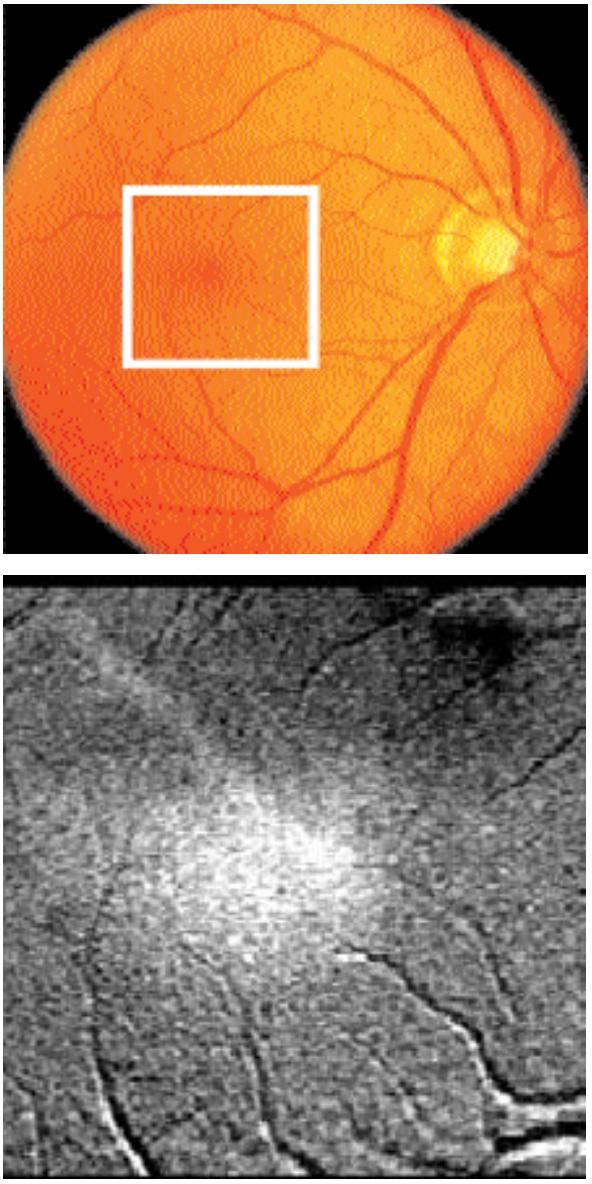

Figure 4. A color image of a normal subject is shown above to provide the scale photopigment map below, which is the central 10 degrees. The map shows that the cone photoreceptors, responsible for capture and signaling of incident light during daylight, have maximum absorption only in the central region of vision.

organized tissues.[1] The retina is only about 200 microns thick at the fovea, the region of best acuity and color vision. Recently, we have shown that with complications of age-related macular degeneration, this region can reach thicknesses of over 600 microns.[2] The challenges in retinal imaging for diagnostic purposes remain enhancing the contrast of relatively transparent tissues and providing a good signal-to-noise ratio despite the limited light returning from the retina and through the pupil.

The cornea is the initial and major refractive element in the eye. It is aspheric. The healthy cornea appears to be transparent, but it produces strong and unwanted reflections and is a polarizing element. One solution to the reflection problem is limiting the focal plane of light returning from the retina by use of a confocal aperture, that is, an aperture in a plane of focus conjugate with the retina.[3-4] The total length of the eye from cornea to retina is about 24 mm. With aging, the corneal tear film is increasingly likely to be altered. This results in discomfort from dry eyes, and also makes this air-tissue interface non-uniform, altering on a fine scale both focusing and interface properties.

The pupil controls not only the amount of light falling onto the retina but also the amount of light returning out of the eye. The diameter of the pupil controls the axial resolution for *in vivo* optical sectioning. The best axial resolution theoretically possible would be obtained with an 8 mm diameter pupil about 17 mm anterior to the retina. However, outside the central cornea, there are usually more significant aberrations. Older adults have smaller pupils than younger ones, as shown by the arrows in the diagram at the right of Figure 1. In the dim illumination used in many eye care examination rooms, a typical pupil diameter is 7.5 mm for 20 year olds, but 4.5 mm or less for 75 year olds.[5] Medications to dilate the pupil become

less effective in older patients. Small pupil size compounds the problem of low light return from the retina and limits the axial resolution of confocal imaging techniques. For this reason, in the case of older individuals, retinal imaging instruments cannot rely on the presence of a large diameter pupil.

The best known change that accompanies aging is the increase in scatter and absorption of the ocular media. The lens becomes increasingly large, undergoes a shape change, and becomes less clear. The optics of the human lens have been studied extensively in the living eye using Scheimpflug photography by Koretz and colleagues.[6-7] Even a lens considered clear for an older eye will have these changes, as shown by the pair of lenses for a 24 year old and a 68 year old in the inset in Figure 1. The vitreous body, clear in younger eyes, develops opacities with age and become hazy with disease. Loss of transmission through the ocular media is particularly severe for short-wavelength light.

Our research has shown previously that the deeper layers of the retina, where many sight-threatening diseases have their primary locus, are better penetrated by near infrared light, regardless of the clarity of the ocular media. The main absorbing pigments in the eye are blood, hemoglobin, photopigments, macular pigments, and water, all of which have broad absorption spectra.[8] There is a relatively absorption-free wavelength range from about 830-890 nm that is well-matched to silicon-based photodetectors with high sensitivity. This permits digital imaging of the retina at video rates and higher. Techniques employing near infrared imaging and red imaging with laser scanning provide good penetration, yet permit control of the light that is detected.[8-10] Two problems arose with initial near infrared techniques that now have partial solutions, as discussed below: controlling the light that readily scatters under conditions of little absorption and illuminating with near infrared sources having good beam shape and power stability.

The best known change that accompanies aging is the increase in scatter and absorption of the ocular media.

A variety of these advanced techniques are now used in clinical settings for the management of a number of different diseases, which cause far more complicated light-tissue interactions than those found in the young, healthy eye. Advanced imaging techniques are particularly helpful in disease that specifically affects the retina in an aged eye: age-related macular degeneration, choroidal melanoma, macular holes, diabetes, cystoid macular edema, and glaucoma.[11-17] The use of confocal apertures and stops, placed in an optical plane conjugate to the tissue of interest, helps control the proportion of directly backscattered light to multiply scattered light in the sample returning from the retina. The view of the same retinal area varies greatly with wavelength, and depending on whether directly backscattered light is collected through a pinhole aperture or multiply scattered light is sampled using an annular or offset aperture (Figure 2). Light that strikes the well-ordered structure of the retinal nerve fiber layer is likely to be directly backscattered (Figure 3). This permits stacks of images varying in the axial dimension to be used in topographic measurements, such as the elevation of the retina caused by underlying disease.[2,10, 15-16] When light strikes the nerve fiber layer, a larger proportion of the incident light is usually returned compared with the poorer penetration into and return from deeper layers, regardless of the technique used. When polarized light is used, the retinal nerve fibers add retardance proportional to the layer thickness, and Dr. Andreas Dreher and colleagues have developed a clinical test based on scanning laser polarimetry for use with glaucoma and optic nerve diseases[17] which cause loss of nerve fibers.

The structure of the retina

The retina contains millions of cells, most about 1-5 microns in diameter at the cell body. There are six main types of neural cells in the retina; of these, the photoreceptor cells are the ones responsible for capturing light. They lie beneath the layers containing the other five types, as shown at the bottom right of Figure 1. The deepest portion of photoreceptor cells contains the

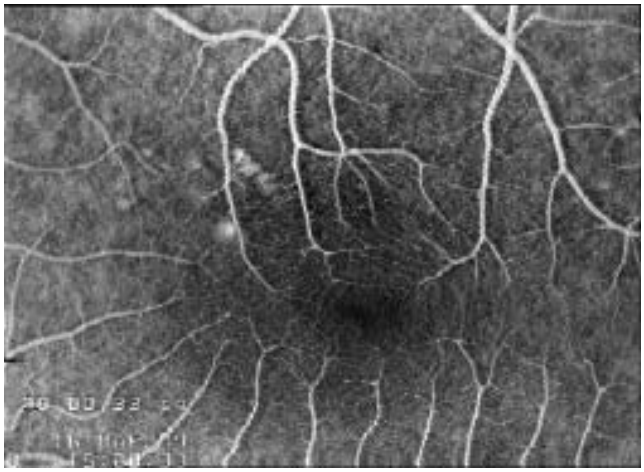

Figure 5. A fluorescein angiogram emphasizes the thin layer of retinal capillaries in central vision, as well as the larger retinal vessels. Blood vessels most visible prior to the dye diffusing through the vessel walls. The patient has diabetes, and the cyst visualized as the diffusely brighter circle indicates more rapid escape of dye from the vessels. This image is similar in size to the the smaller ones in Figure 2, but used 488 nm excitation and a long pass filter.

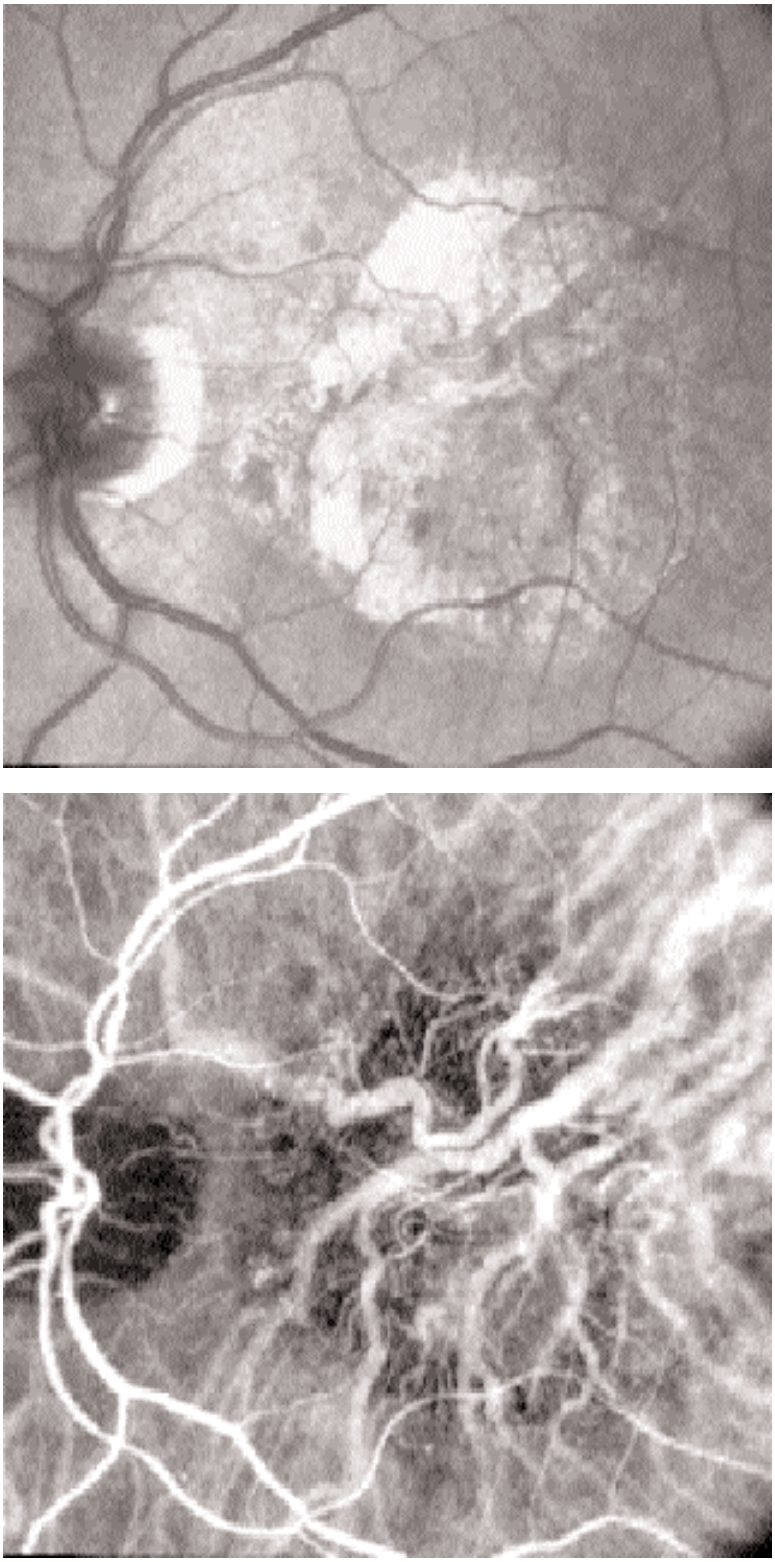

Figure 6. A view of both the retinal and choroidal circulations is afforded by the retinal atrophy in the eye of a patient with age-related macular degeneration, a part of the study with Laser Diagnostic Technology. The top figure is a confocal image at 790 nm, showing 30 degrees of retina, with the large choroidal vessels visible through the atrophic part of the retina. On the left side is a dark circle of uncontrolled new vessel growth. The bottom figure is an indocyanine green angiogram, acquired simultaneously, corroborating both the atrophy and the new blood vessels.

photopigment that initiates vision. We have used a type of functional imaging, retinal densitometry, to image the distribution of photopigment contained within the photoreceptor cells of the living eye.[18] (See Figure 4.) This work builds on a long tradition of measuring the returning light from a region of interest on the retina, both before and after light exposure strong enough to reduce the concentration of photopigment. The resulting measurements indicate, on a scale of about 40 microns, the optical density of the photopigment, an indication of the health of the living retina at that location.

For some diagnostic purposes, the neural retina itself is of interest; for others, the blood vessels are of interest. The human retina is served by two separate circulations. The retinal circulation lies largely in the more anterior retinal layers so that blood vessels and blood cells can obscure the neural cells beneath them. The choroidal circulation lies beneath the retina and the retinal pigment epithelial cells that nourish its deeper layers. To enhance the view of normal and diseased blood vessels, a contrast agent is added. The most common is sodium fluorescein, which can clearly visualize vessels in the macula as small as capillaries (Figure 5). Fluorescein angiography is performed with a short wavelength excitation, such as a 488 nm Argon laser line.[19] Choroidal circulation is observed better with indocyanine green angiography, which uses near infrared excitation and emission (Figure 6).

Novel light sources

A wide variety of laser sources have been used to perform imaging in patients. Examples include the vertical cavity surface emitting laser (VCSEL) at 850 nm used in collaboration with Dr. Jack L. Jewell to produce the image depicted in Figure 3. A tunable wavelength Ti:sapphire laser was used to determine the wavelength range that is optimal for infrared imaging and indocyanine green angiography.[12] Thus, before testing it was expected that the VCSEL would produce an excellent image despite the conventional wisdom of poor imaging with such long wavelengths. A Chr:Li:SaF provided a convenient tunable source for infrared imag-

ing, invisible to the patient.[20] The tunable laser research was performed in collaboration with Dr. Peter Moulton and Mr. Henry Zenzie. We find that these sources, given the excellent beam quality and longer wavelengths, provide superior imaging and may therefore allow the clinician to use a non-invasive test rather than, or as a precursor to, injecting dye for angiography.[10, 12-13]

Looking forward

Instrumentation for retinal imaging continues to shrink in size to the point of approaching true portability. Use of VCSELs as sources will help accomplish this goal. In addition, VCSELs may be multiplexed at high rates, so that images with directly backscattered and multiply scattered light may be acquired using line-by-line alternation.[21] Computations based on stacks of images may be made from both directly backscattered and multiply scattered light, so that images containing vastly different features automatically have good registration.

A chief limitation in retinal imaging has been that humans move their eyes in an uncontrollable and unpredictable manner. A new retinal tracking procedure has been developed by R.D. Ferguson and colleagues. Together, we have used this procedure to stabilize the position of both the retina and the pupil with respect to the imaging instrument.[22] This allows longer samples to be averaged over several frames, increasing the signal-to-noise ratio of weak signals. It is anticipated that use of this procedure will allow the highly magnified imaging necessary to see fine structures, such as individual cells or small pathological structures.

Another limitation has been that the optics of the human eye have sufficient aberrations to limit retinal image quality. The active optics described initially by Andreas Dreher and colleagues[23] may become a reality, in that it corrects for the aberrations to improve image quality.

Acknowledgments

Peter Mallen produced the color diagram of the eye and incorporated the information from several sources. Dr. Jane Koretz loaned us slides of two human lenses from the Scheimpflug photography study. Drs. Stephen A. Burns and Robert H. Webb of the Schepens Eye Research Institute are long-term collaborators on this research. Drs. Andreas W. Dreher and Qienyuan Zhou of Laser Diagnostic Technologies collaborate on the multiply scattered light studies, and Dr. Paul Tornambe collaborated on the study shown in Figure 6. This research has had recent support from EYO7624, Wold Foundation, Molinari Foundation, and the Lions Club of Massachusetts to A.E. Elsner, the Center of Excellence Grant DE-FG 02-91ER61229 to R. H. Webb, and EY11040 and EY12178 to A.W. Dreher.

References

1. R. W. Rodieck, *The First Steps in Seeing* (Sinaur: Sunderland, MA, 1998).
2. C. Kunze, *et al.*, "Spatial extent of pigment epithelial detachments in age-related macular degeneration," *Ophthalmology*, **9**, 1830–40 (1999).
3. R.H. Webb, *et al.*, "Confocal scanning laser ophthalmoscope," *Appl. Optics*, **26**, 1492–9 (1987).
4. A.W. Dreher, *et al.*, "Reproducibility of topographic measurements of the normal and glaucomatous optic nerve head with the laser tomographic scanner," *Am. J. Ophthalmology*, **111**, 221–9 (1991).
5. B. Winn, *et al.*, "Factors affecting light-adapted pupil size in normal human subjects," *Invest. Ophthalmol. Vis. Sci.*, **35**, 1132–7 (1994).
6. J.F. Koretz, *et al.*, "Accommodation and presbyopia in the human eye: evaluation of in vivo measurement techniques," *Appl. Optics*, **28**, 1097–1101 (1989).
7. C.A. Cook, "Aging of the human crystalline lens and anterior segment," *Vis. Res.*, **34**, 2945–54 (1994).
8. A.E. Elsner, *et al.*, "Infrared imaging of subretinal structures in the human ocular fundus," *Vis. Res.*, **36**, 191–205 (1996).
9. A.E. Elsner, *et al.*, "Reflectometry with a scanning laser ophthalmoscope," *Appl. Optics*, **31**, 3697–710, 1992.
10. A.E. Elsner, *et al.*, "New devices in retinal imaging and functional evaluation," *Practical Atlas of Retinal Disease and Therapy* (Lippincott-Raven: New York, 2nd edition), pp. 19–55 (1998). **(A.Q. you have two #10 references...are all reference numbers correct?)**
10. L.M. Kelley, *et al.*, "Scanning laser ophthalmoscope imaging of age related macular degeneration and neoplasms," *J. Ophthalmic Photography*, **3**, 89–94 (1997).
11. M.E. Hartnett and A.E. Elsner, "Characteristics of exudative age-related macular degeneration determined in vivo with confocal direct and indirect infrared imaging," *Ophthalmology*, **103**, 58–71 (1996).
12. M.E. Hartnett, *et al.*, "Deep retinal vascular anomalous complexes in advanced age-related macular degeneration," *Ophthalmology*, **103**, 2042–53 (1996).
13. A. Remky, *et al.*, "Digital imaging of central serous retinopathy using infrared illumination," *German J. Ophthalmology*, **4**, 203–6 (1995).
14. A. Remky, *et al.*, "Infrared imaging of cystoid macular edema," *Graefe's Arch. Clin. Exp. Ophthalmol.*, **237**, 897–901 (1999).
15. E. Beausencourt, *et al.*, "Quantitative analysis of macular holes with scanning laser tomography," *Ophthalmology*, **104**, 2018–29 (1997).
16. E. Beausencourt, *et al.*, "Infrared scanning laser tomography of macular cysts," *Ophthalmology*, **107**, 375–85 (2000).
17. N.T. Choplin, *et al.*, "Differentiating patients with glaucoma from glaucoma suspects and normal subjects by nerve fiber layer assessment with scanning laser polarimetry," *Ophthalmology*, **105**, 2068–76 (1998).
18. A.E. Elsner, *et al.*, "Foveal cone photopigment distribution: small alterations associated with macular pigment distribution," *Investigative Ophthalmol. Vis. Sci.*, **39**, 2394–404 (1998).
19. A. Remky, *et al.*, "Short-wavelength automated perimetry and capillary density in early diabetic maculopathy," *Invest. Ophthalmol. Vis. Sci.*, **41**, 274–82 (2000).
20. A. Remky, *et al.*, "Angioscotometry with the SLO: comparison of the effect of different wavelengths," *Invest. Ophthalmol. Vis. Sci.*, **37**, 2350–66 (1996).
21. A.E. Elsner, *et al.*, "Multiply scattered light tomography: vertical cavity surface emitting laser array used for imaging subretinal structures," *Lasers and Light in Ophthalmology*, **8**, 193–202 (1998).
22. R.D. Ferguson, *et al.*, "A new approach to retinal tracking for image stabilization: initial results for the scanning laser ophthalmoscope," *Vision Science and Its Applications, OSA Technical Digest*, 175–8 (2000).
23. A.W. Dreher, *et al.*, "Active-optical depth resolution improvement of the laser tomographic scanner," *Appl. Optics*, **28**, 804–8 (1989).

Ann E. Elsner, Joseph P. Walker, Glenn L. Wing, Paul A. Raskauskas and Donald C. Fletcher have current appointments at the Schepens Eye Research Institute in Boston, MA. Andreas Remky, formerly of the Schepens Eye Research Institute, has been in the Augenklinik der RWTH, in Aachen, Germany, since 1995. Joseph P. Walker, Glenn L. Wing, Paul A. Raskauskas, Linda M. Kelley and Cheryl Kiesel have their clinical practice at the Retinal Consultants of SW Florida in Ft. Meyers, FL. Dr. Elsner may be reached at elsner@vision.eri.harvard.edu.